

Helen McGuinness

Anatomy & Physiology

5th Edition

 DYNAMIC
LEARNING

 HODDER
EDUCATION
LEARN MORE



Anatomy and Physiology 5th Edition is available as a **Whiteboard eTextbook** and **Student eTextbook**.

Whiteboard eTextbooks are online interactive versions of the printed textbook that enable teachers to:

- Display interactive pages to their class
- Add notes and highlight areas
- Add double page spreads into lesson plans

Student eTextbooks are downloadable versions of the printed textbooks that teachers can assign to students. Students can:

- Download and view them on any device or browser
- Add, edit and synchronise notes across two devices
- Access their personal copy on the move

Find out more and sign up for a free trial – visit: www.hoddereducation.co.uk/dynamiclearning

Helen McGuinness

Anatomy & Physiology



Although every effort has been made to ensure that website addresses are correct at time of going to press, Hodder Education cannot be held responsible for the content of any website mentioned in this book. It is sometimes possible to find a relocated web page by typing in the address of the home page for a website in the URL window of your browser.

Hachette UK's policy is to use papers that are natural, renewable and recyclable products and made from wood grown in sustainable forests. The logging and manufacturing processes are expected to conform to the environmental regulations of the country of origin.

Orders: please contact Bookpoint Ltd, 130 Milton Park, Abingdon, Oxon OX14 4SB. Telephone: (44) 01235 827720. Fax: (44) 01235 400454. Email education@bookpoint.co.uk Lines are open from 9 a.m. to 5 p.m., Monday to Saturday, with a 24-hour message answering service. You can also order through our website: www.hoddereducation.co.uk

ISBN: 978 1510 435179

© Helen McGuinness 2018

First published in 2018 by
Hodder Education,
An Hachette UK Company
Carmelite House
50 Victoria Embankment
London EC4Y 0DZ

www.hoddereducation.co.uk

Impression number 10 9 8 7 6 5 4 3 2 1

Year 2021 2020 2019 2018

All rights reserved. Apart from any use permitted under UK copyright law, no part of this publication may be reproduced or transmitted in any form or by any means, electronic or mechanical, including photocopying and recording, or held within any information storage and retrieval system, without permission in writing from the publisher or under licence from the Copyright Licensing Agency Limited. Further details of such licences (for reprographic reproduction) may be obtained from the Copyright Licensing Agency Limited, Saffron House, 6–10 Kirby Street, London EC1N 8TS.

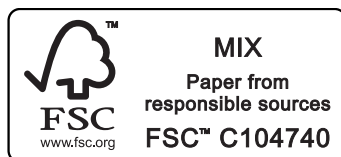Cover photo © Sebastian Kaulitzki/123RF.com

Illustrations by Barking Dog Art

Typeset in India by Integra Software Services Pvt. Ltd, Pondicherry, India

Printed in Slovenia

A catalogue record for this title is available from the British Library.



Contents

Acknowledgements	iv
How to use this book	vi
1 An introduction to anatomy and physiology: how the body is organised	1
2 Cells and tissues	10
3 The skin, hair and nails	37
4 The skeletal system	96
5 The muscular system	128
6 The cardiovascular system	173
7 The lymphatic system and immunity	211
8 The respiratory system	230
9 The nervous system	246
10 The endocrine system	278
11 The reproductive system	299
12 The digestive system	318
13 The renal system	341
Index	353

Acknowledgements

Whilst preparing the original text of this book back in the early 1990s, I never dreamed it would be in circulation for over 20 years and now be in its fifth edition, with an accompanying workbook.

Firstly, I would like to extend my most significant thanks to my husband Mark for his constant love, help, support and understanding, along with his constructive comments made in the updating of this book.

To my late mum, Valerie, whose eternal love, words of encouragement and belief in my abilities continue to motivate and inspire me to this day.

To my dear friend Dee Chase (aka Mum Dee), for her constant love, belief, support and encouragement of my work and writing.

To Dr Nathan Moss, for help in checking the accuracy of the text on pathologies.

I will always be greatly indebted to Deirdre Moynihan for her professional help and contributions throughout the preparation of the original text back in 1995 when the book was in its infancy.

Special thanks go to Linda Biles, Head of Beauty Therapy at Chichester College, who has encouraged and supported the update of this latest edition and offered her invaluable suggestions and constructive comments.

I would like to thank all the students, colleges and lecturers who have used this book over the past 20 years and who have been most encouraging and supportive of my work.

This book is devoted to our beautiful daughter, Grace.

Helen J. McGuinness

Picture credits

The publishers would like to thank the following for permission to reproduce copyright material:

pp.1, 10, 37 © Nobilior/stock.adobe.com; p. 13 © Alexey Bezrodny/123RF; p. 21 © Designua/stock.adobe.com; p. 47 © Reineg/stock.adobe.com; p. 49 © Designua/stock.adobe.com; p. 51 *l* © M eye view/Shutterstock.com, *r* © Daxiao Productions/stock.adobe.com; p. 52 © Jo Ann Snover/stock.adobe.com; p. 55 *l* © Juergen Faelchle/Shutterstock.com, *r* © Mediscan/Alamy Stock Photo; p. 56 *l* © Biophoto Associates/Science Photo Library, *tr* © vchalup/stock.adobe.com, *br* © Big Foot Productions/Shutterstock.com; p. 57 *t* © Guentermanaus/Shutterstock.com, *m* © Tony McConnell/Science Photo Library, *b* © Dr P. Marazzi/Science Photo Library; p. 58 © lpen/Shutterstock.com; p. 59 © Kiselev Andrey Valerevich/Shutterstock.com; p. 61 *t* © goodluz/stock.adobe.com, *2nd* © Iconogenic/stock.adobe.com, *3rd* © Rido/stock.adobe.com, *4th* © kmwphotography, *b* © Diego cervo/stock.adobe.com; p. 72 *tl* © Kyrlyo Glivin/Shutterstock, *bl* © Dr P. Marazzi/Science Photo Library, *tr* © MEDICAL PHOTO NHS LOTHIAN/SCIENCE PHOTO LIBRARY PRINCESS MARGARET ROSE ORTHOPAEDIC HOSPITAL, *br* © Nataly Studio/Shutterstock.com; p. 73 *tl* © Dr Jeremy Burgess/Science Photo Library, *bl* © Science Photo Library, *tr* © Mediscan/Alamy Stock Photo, *br* © Dr P. Marazzi/Science Photo Library; p. 74 *tl* © Pictoplay/Shutterstock.com, *bl* Ccoolephoto/istock, *tr* © Dr P. Marazzi/Science Photo Library, *br* © Ohishiftl/stock.adobe.com; p. 75 *tl* © John Radcliffe Hospital/

Science Photo Library, *ml* © Science Photo Library, *bl* © Dr P. Marazzi/Science Photo Library, *tr*
© Jajavenue/Shutterstock.com, *br* Simon_L/istock; p. 76 *tl* © Dr P. Marazzi/Science Photo Library, *ml* ©
Dr P. Marazzi/Science Photo Library, *bl* © Dr P. Marazzi/Science Photo Library, *tr* © artem_goncharov/
stock.adobe.com, *br* © Dr P. Marazzi/Science Photo Library; p. 77 *t* © Western Ophthalmic Hospital/
Science Photo Library, *b* © Science Photo Library; p. 78 *tl* © Dr P. Marazzi/Science Photo Library, *ml* ©
Dr Chris Hale/Science Photo Library, *bl* © Dr P. Marazzi/Science Photo Library, *tr* © Sue Ford/Science Photo
Library, *br* © CNRI/Science Photo Library; p. 79 *tl* © BIOPHOTO ASSOCIATES/Science Photo Library, *bl* ©
CNRI/Science Photo Library, *tr* © Dr P. Marazzi/Science Photo Library, *br* © John Wilson/Science Photo
Library; p. 80 *tl* © BSIP/Science Photo Library, *bl* © Dr P. Marazzi/Science Photo Library, *r* © Kalcutta/
Shutterstock.com; p. 81 *t* © CDC/BSIP SA/Alamy Stock Photo, *b* © Dr P. Marazzi/Science Photo Library;
p. 82 © Dr P. Marazzi/Science Photo Library; p. 83 © Dr P. Marazzi/Science Photo Library; p. 84 *l* ©
Dr P. Marazzi/Science Photo Library, *r* © ISM/Science Photo Library; p. 85 *tl* © Nancynan/Shutterstock.
com, *bl* © Dr P. Marazzi/Science Photo Library, *r* © Science Photo Library; p. 86 *l* © J.F. Wilson/Science
Photo Library, *tr* © Dr. P. Marazzi/Science Photo Library, *br* © Science Photo Library; p. 87
© Dr. P. Marazzi/Science Photo Library; p. 88 *tl* © Dr. P. Marazzi/Science Photo Library, *bl* © Dr. P. Marazzi/
Science Photo Library, *r* © Dr. P. Marazzi/Science Photo Library; p. 89 *t* © CNRI/Science Photo Library, *b*
© Dr. P. Marazzi/Science Photo Library; p. 90 © Dr. P. Marazzi/Science Photo Library; p.96 © Nobileior/
stock.adobe.com; p. 99 © Designua/stock.adobe.com; p. 120 *l* © John R. Foster/Science Photo Library, *r*
© Sue Ford/Science Photo Library; p. 121 © Horus2017/Shutterstock.com; p.128 © Nobileior/stock.adobe.
com; p. 130 © Andrea Danti/stock.adobe.com; p. 135 © Peter Lamb/123RF; p. 138 © Sebastian Kaulitzki/
stock.adobe.com; p. 139 © 7activestudio/stock.adobe.com; p. 140 © Lukaves/123RF; p.173 © Nobileior/
stock.adobe.com; p. 175 © Designua/stock.adobe.com; p. 177 © Designua/123RF; p. 178 © Designua/
stock.adobe.com; p.211 © Nobileior/stock.adobe.com; p. 221 *l* © PIXOLOGICSTUDIO/Science Photo
Library, *r* © Alila Medical Media/stock.adobe.com; p. 222 © Nerthuz/stock.adobe.com; p.230 © Nobileior/
stock.adobe.com; p. 233 © Peter Hermes Furian/stock.adobe.com; p.246 © Nobileior/stock.adobe.com;
p. 252 © Joshya/stock.adobe.com; p. 259 © Udaix/123RF; p. 262 © Christos Georghiou/stock.adobe.com;
p. 263 © Peter Lamb/123RF; p. 266 © Vonuk/stock.adobe.com; p.278 © Nobileior/stock.adobe.com; p. 283
© Designua/123RF; p. 284 © Reineg/stock.adobe.com; p. 290 © Designua/123RF; p.299 © Nobileior/stock.
adobe.com; p. 306 © Tigatelu/stock.adobe.com; pp. 318, 341 © Nobileior/stock.adobe.com.

Every effort has been made to trace and acknowledge ownership of copyright. The publishers will be glad to make suitable arrangements with any copyright holders whom it has not been possible to contact.

How to use this book

Dear Colleague,

This book, now in its fifth edition, has been designed for those studying beauty therapy, complementary therapies or any subject that requires a sound foundation knowledge of anatomy and physiology.

This edition has been completely revised to bring it in line with the latest anatomy and physiology specifications of the Technical/Advanced Level qualifications.

As well as new and updated content, additional new features include an expanded introductory chapter on how the body is organised, key word glossaries at the end of the chapter, new and improved illustrations and photographs, and expanded end-of-chapter revision summaries and test your knowledge questions.

Each chapter gives an overview of a system and why it is of significance to a therapist, has a list of learning objectives, and is full of interesting facts and information to help stimulate your learning.

At the end of each chapter there is a link to other body systems to help to put the subject into context, showing how the body systems work as a whole to keep us in balance, along with a comprehensive revision summary and test your knowledge questions in multiple choice and new exam-style formats.

Once you have studied the contents of this textbook, there is a new accompanying workbook available to help test your knowledge and prepare you for assessments and examinations. Contents of the workbook include a range of activities including additional multiple choice and exam-style questions, labelling, matching the key words, sorting, and filling in the blanks.

Anatomy and physiology is a fascinating subject and I sincerely hope that this new edition provides you with an improved learning experience.

Helen J. McGuinness

Answers are available online at www.hoddereducation.co.uk/Anatomy-and-Physiology-Extras

1 An introduction to anatomy and physiology: how the body is organised

Introduction

Before we begin the fascinating journey of learning about how the body works, let's look at the terminology associated with the study of the human body.

- **Anatomy** is the study of the **structure and location** of body parts.
- **Physiology** is the study of the **function** of body parts.

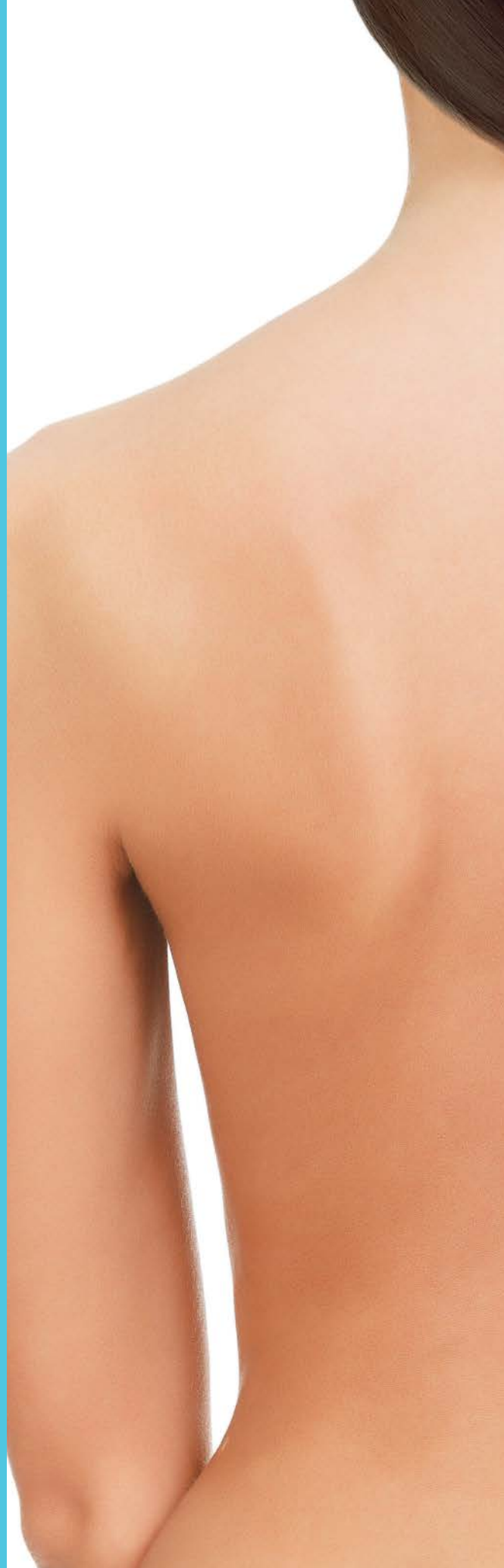It is very important to co-ordinate these two subjects because knowledge of structure is incomplete without the knowledge of function, and the knowledge of function is incomplete without the knowledge of structure.

- **Pathology** is the study of **disease** in the body. At the end of each chapter in this book there is a section on the common pathologies associated with a system of the body.

OBJECTIVES

By the end of this chapter you will understand:

- anatomical directional terminology used to give a precise description of a body part
- anatomical planes, which divide the body into sections
- anatomical regional terms, which refer to specific areas of the body
- the main body cavities that divide the body and its internal organs into sections.



KEY FACT

Knowing where parts of the body are located will help your understanding as you build up a picture of how they function.

In practice

Think of the structure of the heart and all its chambers and valves. Visualising the individual structures (the anatomy), can help you to understand how the blood flows through the heart and how the heart beats. You are relating anatomy to function or physiology.

The body as a map

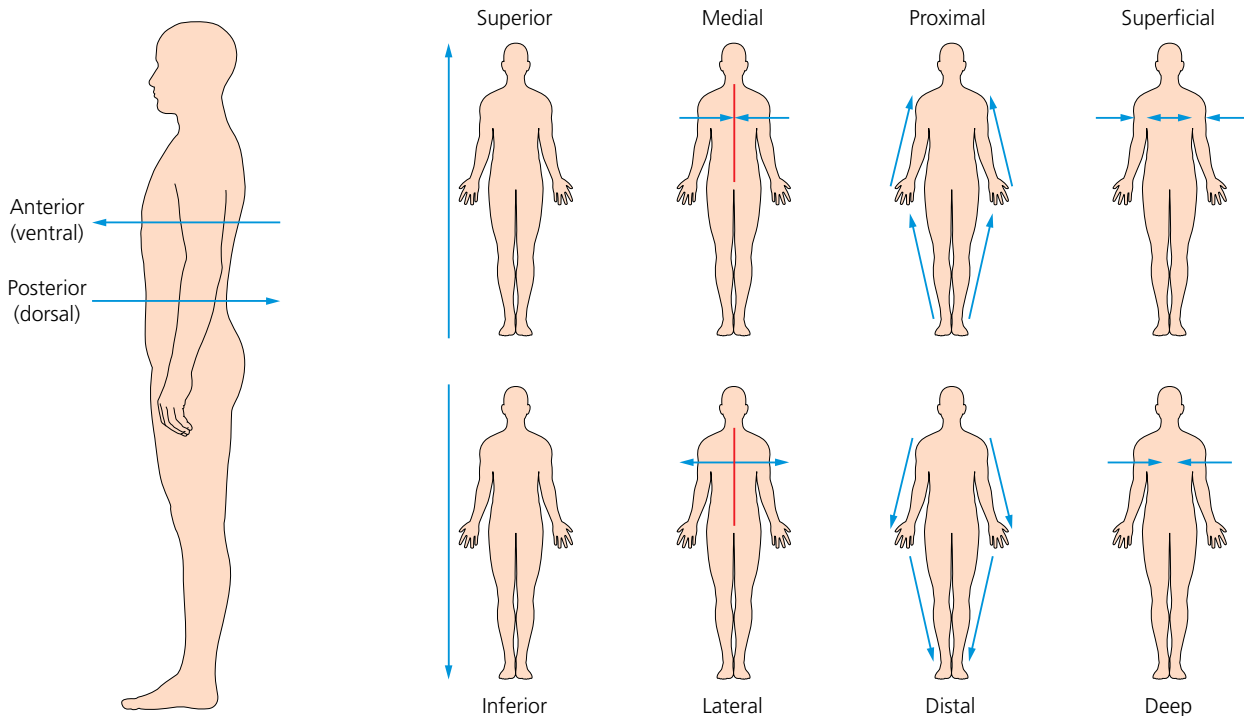
The body may be likened to a map and the key to locating and understanding the parts of the body is directional terminology.

Anatomical terminology

When studying anatomy and physiology, you should use directional terminology to give precise descriptions when referring to the exact location of a body part or structure. In anatomical terminology, all parts of the body are described in relation to other body parts using a standardised body position called the **anatomical position**.

In this position, the body is erect and facing forwards, arms to the side, palms are facing forwards with the thumbs to the side, and the feet slightly apart with toes pointing forwards. There is an imaginary line running down the centre or midline of the body.

Learning anatomical terminology is like learning a new language!



▲ Anatomical terms

Anatomical directional terms

The anatomical terms in Table 1.1 will help you to be specific when describing the position of a body part.

Study tip

The directional terms have been organised into pairs for ease of learning; once you know one term, it is easier to learn the opposite term.

Table 1.1 Anatomical directional terms

Anatomical directional term	Definition	In practice
Anterior (or ventral)	Front surface of the body, or structure	The biceps muscle is on the anterior surface of the upper arm
Posterior (or dorsal)	Back surface of the body, or structure	The triceps muscle is on the posterior surface of the upper arm
Superficial	Near the body surface	The most superficial layer of the skin is the epidermis
Deep	Further from the body surface	The dermis is deep to the epidermis
Lateral	Away from the midline	The radius is lateral to the ulna
Medial	Towards the midline	The ulna is medial to the radius
Superior	Situated towards the head, or above a point of reference	The shoulder joint is superior to the elbow joint
Inferior	Situated away from the head or below a point of reference	The intestines are inferior to the stomach
Central	At or near the centre	The brain and spinal cord are part of the central nervous system
Peripheral	Away from the centre; outer part of the body	Peripheral vision allows us to see things out of main focus
Proximal	Nearest to the point of reference	The wrist joint is proximal to the elbow joint
Distal	Furthest away from the point of reference	The shoulder joint is distal to the wrist joint
Prone	Lying face down in a horizontal position	When receiving a back massage a client lies prone
Supine	Lying face up in a horizontal position	When receiving a facial a client lies supine
Caudal	Away from the head, or below a point of reference	The coccyx (tail bone) is an example of a caudal position
Cranial (or cephalic)	Relating to the head end or skull (cranium)	The brain is located in the cranial cavity
Palmar	Relating to the palm side of the hand	The thenar muscle is on the palmar surface of the hand
Plantar	Relating to the sole of the foot	There is a central tendon on the plantar surface of the foot
Ipsilateral	On the same side as another structure	The right radius and right humerus are ipsilateral
Contralateral	On the opposite side to another structure	The right and left kidneys are contralateral

Other directional terms

- **Longitudinal:** running in the direction of the length of the body or any of its parts.
- **Visceral:** used when referring to any internal organs, specifically those in the main body cavity (intestines, liver, stomach, for example).
- **Parietal:** used to refer to things within the body that are attached to the inside of the body cavity or a hollow structure.
- **Internal:** near the inside.
- **External:** near the outside.



Activity

Make up a blank template of the face and body. Design some small labels, each with an anatomical region on it (for example buccal, cervical). Attach the labels onto the facial/body template to indicate where each region is located.


Anatomical terms applied to movement

There are several anatomical terms relating to movement in the body, such as **adduction** and **abduction**. These are defined in Chapter 5, The muscular system.

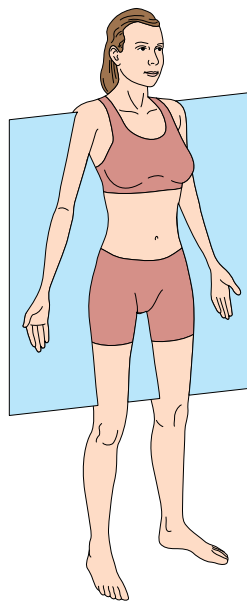
The anatomical planes of the body

In the study of anatomy, there are three planes that separate the body into sections:

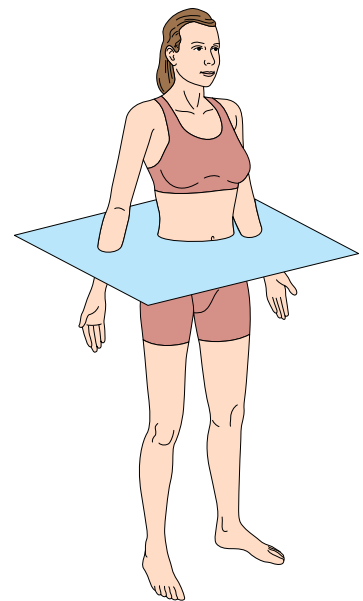
- 1 The **median or sagittal plane:** a vertical plane that divides the body lengthwise into right and left sections.
- 2 The **frontal or coronal plane:** divides the body into a front (anterior) portion and a rear (posterior) section.
- 3 The **transverse plane:** a horizontal plane that divides the body into top (superior) and bottom (inferior) sections.



Sagittal plane



Frontal/coronal plane



Transverse plane

▲ Anatomical planes of the body

The anatomical regions of the body

Just like regions on a map, the anatomical regions of the body refer to certain body areas.

The body is divided into:

- head and neck
- trunk
- upper limbs (arms)
- lower limbs (legs).

Tables 1.2, 1.3, 1.4 and 1.5 will help you to learn the correct terminology for each region.

The head and neck

Table 1.2 Anatomical regional terms of the head and neck

Anatomical regional term	Area of body
Buccal	Cheek
Cephalic	Head
Cranial	Skull
Cervical	Neck
Facial	Face
Frontal	Forehead
Mental	Chin
Nasal	Nose
Occipital	Back of head/skull
Ophthalmic/orbital	Eyes
Oral	Mouth
Otic	Ear

The upper and lower limbs

Table 1.3 Anatomical regions of the upper limbs

Anatomical term	Area of the body
Brachial	Upper arm
Carpal	Wrist
Cubital	Elbow
Digital/phalangeal	Fingers (and toes, see Table 1.4)
Forearm	Lower arm
Palmar	Palm of hand

Table 1.4 Anatomical regions of the lower limbs

Anatomical term	Area of the body
Calcaneal	Heel
Crural	Leg or thigh
Digital/phalangeal	Toes (and fingers, see Table 1.3)
Femoral	Thigh
Patellar	Knee cap
Pedal	Foot
Plantar	Sole of foot
Popliteal	Hollow behind knee
Sural	Calf
Tarsal	Ankle

The trunk

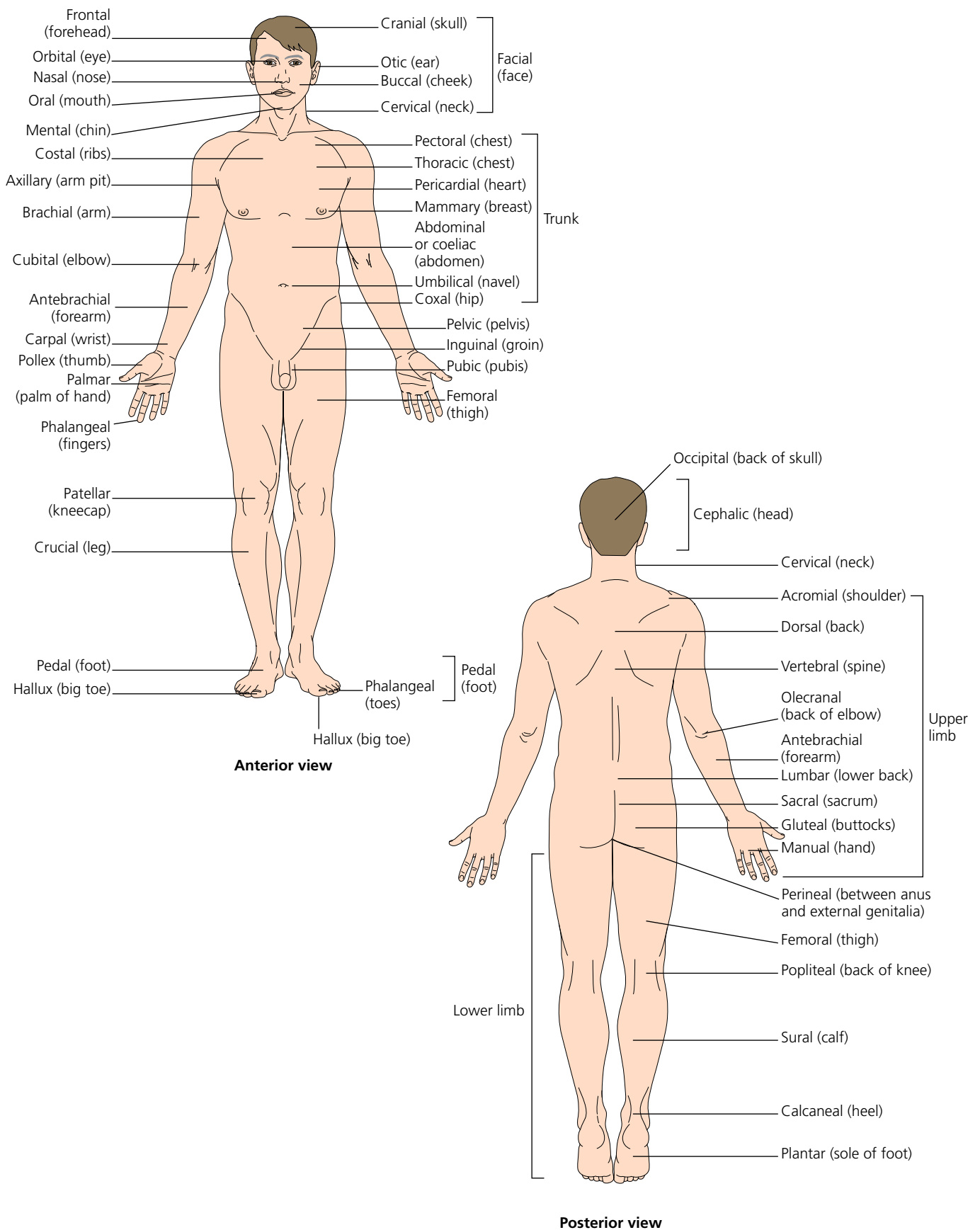
Table 1.5 Anatomical regional terms of the trunk (thorax and abdomen)

Anatomical regional term	Area of body
Abdominal	Abdomen
Axillary	Armpit
Coeliac	Abdomen
Costal	Ribs
Gluteal	Buttocks
Inguinal	Groin
Lumbar	Lower back
Mammary	Breast
Pectoral	Chest
Pelvic	Pelvis/lower abdomen
Pericardial	Heart
Perineal	Between anus and external genitalia
Pubic	Pubis (front of pelvis)
Sacral	Sacrum
Thoracic	Thorax (chest cavity)
Umbilical	Navel
Vertebral	Spine/backbone

Other general anatomical regional terms

Cutaneous: skin

Anatomy & Physiology



▲ Anatomical regional terms

Body cavities

Body cavities are spaces within the body that contain the internal organs.

There are two main cavities in the body:

- 1 the **dorsal cavity**, located in the posterior (back) region of the body
- 2 the **ventral body cavity**, occupying the anterior (front) region of the trunk.

The dorsal cavity is subdivided into two cavities:

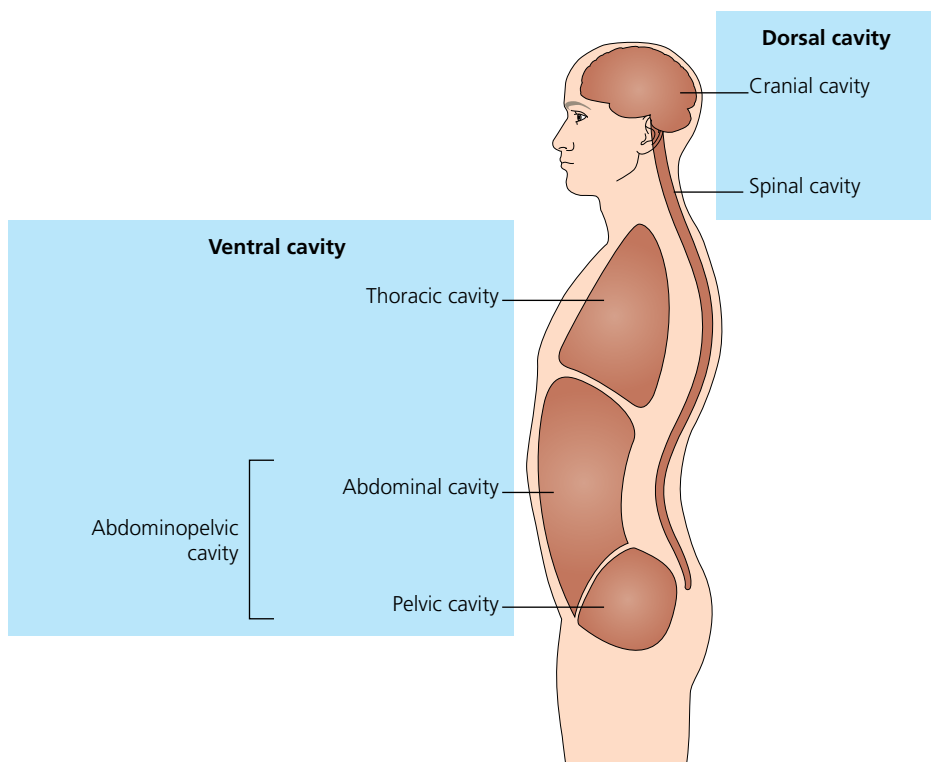
- the **cranial cavity** – encases the brain and is protected by the cranium (skull)
- the **vertebral/spinal cavity** – contains the spinal cord and is protected by the vertebrae.

The ventral cavity is subdivided into:

- the **thoracic cavity** – surrounded by the ribs and chest muscles, the thoracic cavity contains the lungs, heart, trachea, oesophagus and thymus.

It is separated from the abdominal cavity by the diaphragm muscle

- the **abdominopelvic cavity** – consists of both the abdominal and pelvic cavities; contains the liver, stomach, pancreas, spleen, gall bladder, kidneys, and most of the small and large intestines, as well as the bladder and the internal reproductive organs
 - the **abdominal cavity** – contains the stomach, spleen, liver, gall bladder, pancreas, small intestine and most of the large intestine. The abdominal cavity is protected by the muscles of the abdominal wall and partly by the diaphragm and rib cage
 - the **pelvic cavity** – contains the bladder, some of the reproductive organs and the rectum. The pelvic cavity is protected by the pelvic bones.



▲ Body cavities